Nobel Biocare NEWS

Information for the Osseointegration Specialist

Issue 3/2015

You've Got a Date with Destiny

The Nobel Biocare Global Symposium 2016 – at the Waldorf Astoria, New York City, June 23–26, 2016.

World class speakers, hands-on instruction, master classes, forums and social networking opportunities, all in the heart of one of the great cities of the world: This is your big chance to see how innovation can play a decisive part in your day-to-day practice.

By Frederic Love

Next June, the fabled Waldorf Astoria in Manhattan will be hosting the Nobel Biocare Global Symposium under the banner "Where innovation comes to life."

Richard Laube, President of Nobel Biocare, has some simple advice to give potential attendees: "Sign up early—it will be sold out early!"

Thus, as the current year comes to an end, it's high time to make plans to be a part of this preeminent event.

Four days of learning

The symposium's four-day calendar will feature three main themes: Refining and enhancing treatment; digital dentistry; and achieving clinical excellence in challenging situations. Each has a complete schedule of its own, including lectures, master classes and hands-on sessions. Should you choose to follow only one theme, the symposium schedule will allow you to be a part of every single related session.

If, on the other hand, you would like to pick and choose between the different themes and attend individual sessions of special interest in several (or all) of the themes, the Global Symposium will give you the opportunity to design your own learning program.

In addition to a theme-related agenda intertwined with independent study opportunities, Nobel Biocare is arranging a compelling array of forums, including an innovation assembly and a full-day compromised patient forum. Other forums will cover: Partnering for Life; the All-on-4® treatment concept; and dental laboratory workflow. To provide a new generation of dental professionals with their own platform, a NextGen forum will also be held.

> *"When you share your knowledge with someone else, one plus one usually equals three. First you learn about each other's ideas, then you come up with new ones."*
> — Professor Per-Ingvar Brånemark

Getting to know each other

After a busy first-day of lectures, master classes and hands-on sessions, a Thursday welcome gathering will provide a perfect opportunity to unwind and to network with peers from around the world. Here you will be able to raise a glass, enjoy some food and see a display of innovative Nobel Biocare products in the beautiful, historical setting of the Waldorf Astoria.

On Friday evening, Nobel Biocare will host the symposium reception off-site at an exciting venue yet to be revealed. Get ready for an evening to remember with an inspiring blend of diversion and education.

By popular demand

The Scientific Chairmen for the Nobel Biocare Global Symposium 2016 are Drs. Peter Wöhrle of the United States and Bertil Friberg of Sweden. They recently announced that—for the first time at a Nobel Biocare dental event—registered attendees will be able to have a direct impact on the program by voting on various topics and speakers. See the website below for details. The results will be announced a few weeks before the symposium.

Don't miss this opportunity to interact with 150+ world class lecturers and thousands of colleagues from around the world, while exploring the future of dental implants together.

Visit the website below, download the program, and then register for what is sure to be an incomparable experience for everyone involved: the Nobel Biocare Global Symposium in New York! <

→ nobelbiocare.com/global-symposium-2016

In this Issue

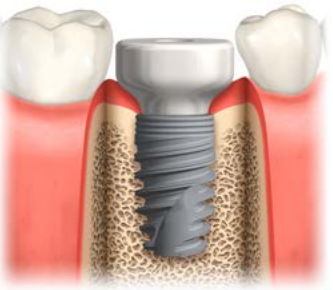



Mr. Steven Pigliacelli

From the President

Richard Laube, President

"Gift or bribe?" That was the cover story of a recent leading dental publication in Germany, *BDIZ EDI konkret*, in response to the new and stricter German guidelines for healthcare professionals.

Germany is not alone. We are observing a worldwide trend towards regulating the relationship between medical device manufacturers and healthcare providers. We have seen an increased frequency of audits by regulators on both our behavior and our customers'. For anyone who has experience with the prescription pharmaceutical industry, this is not new.

Dentistry is also moving toward this "code of conduct"—and we support that. Nobel Biocare has been moving rapidly in the last few years to ensure the highest standard of conduct and, more importantly, to ensure that our valued customers are on the right side of these regulations with us.

We are now signatories of both the AdvaMed and Eucomed codes of conduct. We have also revised our policies and are training our people to work with you in the right way.

I trust you already appreciate our high standards of conduct. While you may experience some modest adjustments, it is all for our mutual benefit and ultimately will enable both of us to serve and treat patients more effectively and efficiently. <

Nobel Biocare

Nobel Biocare NEWS

Published regularly by
Nobel Biocare Services AG

Vol. 17, No. 3, 2015

Editor-in-chief Frederic Love
Managing Editor Jim Mack
Assistant Editor Michael Stuart

Editorial offices
Nobel Biocare News
Herdevägen 11
702 17 Örebro, Sweden

Telephone: +46 19-330680
Telefax: +46 19-330681
e-mail: news.editors@nobelbiocare.com
web: nobelbiocare.com/news

Guided Surgery on Your Terms

Getting it right from the start with guided pilot drilling

When using the NobelGuide treatment concept for guided surgery, two options are available to you today. The fully guided drilling approach can be used or—if you prefer—you can choose guided pilot drilling procedures instead.

A clinician and researcher for 25 years, Dr. Roland Glauser of Zurich, Switzerland, can base every treatment decision on extensive experience. Increasingly, this has led him to opt for guided pilot drilling with NobelGuide. *Nobel Biocare News* caught up with him to find out why.

Dr. Glauser, when did you first start using a guided approach for pilot drilling?

Dr. Roland Glauser: I started with guided pilot drilling some 20 years ago using the first lab-produced surgical templates during initial implant site preparation. Today, things have moved on.

For two years now I have used NobelGuide pilot drill templates for partially guided implant placement. I prefer this approach whenever accurate transfer of a diagnostically established implant position is crucial for an optimal outcome.

What do you see as the main benefits of using a guided surgery template for pilot drilling only?

Glauser: The first drill is so important. Done right, it provides a sound basis for the correct implant position. More bone volume is removed with the first drill than with any other, so with a correct initial osteotomy, the following drills should more or less find their way quite passively.

Guided pilot drilling is ideal because it enables the correct transfer of diagnostics and virtual planning into the surgical field, but you don't need to follow a fully prescribed workflow, with its associated instruments and tooling, to the very end. This can speed up and simplify the entire surgical procedure.

What was the learning curve you experienced with guided pilot drilling?

Glauser: The learning curve relates to precisely maintaining the path established with the pilot drill for each subsequent drill without shifting position. For those just starting with this approach, I recommend checking the established path and any possible shifts in direction by reinserting each drill into the osteotomy.

"Quality is never an accident," says Dr. Roland Glauser, speaking about why he works with Nobel Biocare. "It is the result of good intention and sincere effort."

Surgical templates for edentulous (top) and partially edentulous guided pilot drilling (bottom). Every case is different, which is why NobelGuide offers you alternatives. Choose guided drilling and implant insertion using an individualized surgical template based on your treatment plan. Select either guided pilot drilling or fully guided implant insertion to assure that your treatment is correctly executed-as-planned at the surgical stage.

Are there particular indications for which you tend always to prefer pilot drilling?

Glauser: It usually depends on the bone. If extraction sockets or other bone defect configurations have bone volume that is sufficient for me to predictably guide the subsequent drills and implant into the position defined by the pilot drill, I'll usually go for guided pilot drilling only.

If bone conditions are more demanding and there's a chance that the drills or the implant might shift from the path the pilot drill has set, then I prefer a fully guided approach.

How does NobelClinician assist in planning treatment with guided pilot drilling?

Glauser: NobelClinician makes correct planning easy. For example, when working with narrow spaces, long crowns or significant distances between the incisal or occlusal planes and the bone crest, fully guided templates don't provide the correct fit. With its sleeve offset function, the latest version of NobelClinician makes adjusting the template for pilot drilling simple.

Have you been pleased with the results you have achieved using NobelGuide for pilot drilling?

Glauser: Absolutely! In healed sites the pilot drill approach is absolutely fantastic; it is fast and the outcomes are well in line with the planning. Where bone volume is sufficient, a guided pilot approach has become my favorite. It's precise, easy to implement and can save time while—at the same time—allowing for an accurate transfer of the treatment plan to the case at hand. <

→ More to explore:
Don't miss the infographic on pages 6–7 of this issue! To learn even more about NobelGuide, please visit: nobelbiocare.com/nobelguide.

Science matters

First data on NobelParallel™ Conical Connection (CC)

Interim analysis of the clinical study with immediately loaded NobelParallel (CC) implants demonstrates high implant survival and excellent peri-implant tissue results. (Pozzi et al., EAO2015, poster #419)

This analysis evaluated 32 consecutive patients who received 46 NobelParallel CC implants in healed (n=24) and post-extraction sockets (n=22) to restore single missing teeth in either jaw. All implants were immediately loaded and 3–5 months later received NobelProcera definitive abutments.

After 6 months of follow-up, the implant cumulative survival rate was 100% and the marginal bone remodeling from insertion was –0.51 ±0.34 mm. All implants showed no bleeding on probing and low plaque accumulation, while the papilla index improved over time and was 93.7% at 6 months. No biological or technical complications were observed during this short follow-up. The authors conclude that these favorable results suggest "the novel NobelParallel CC implant can be considered as an effective and biologically beneficial treatment option for immediate loading in partially edentulous patients in both jaws."

→ onlinelibrary.wiley.com/doi/10.1111/clr.250_12679/full

Minimized bone remodeling

Minimal bone remodeling and low surgery-related complications with immediately loaded NobelActive implants placed with NobelGuide (Yamada et al., Int J Oral Maxillofac Implants. 2015. 30(1):184–93)

This prospective study included 50 patients rehabilitated with full-arch maxillary prostheses supported by 290 NobelActive implants placed using guided surgery (NobelGuide). Only a single surgery-related complication was observed involving minor bleeding. Most patients had no postoperative swelling and reported low postoperative pain, likely related to the flapless procedure and extensive preoperative simulation. After 1 year, implant CSR was 98.6%, and all failures occurred in smokers. Bone remodeling was very low (–0.32 ± 0.43 mm), which the authors attribute to the back-taper design of the NobelActive implant.

→ ncbi.nlm.nih.gov/pubmed/25615924

"The manufacturer matters"

An in vitro fatigue test of 4 different abutment types shows Nobel Biocare third-party CAD/CAM abutments have high resistance to failure (Kelly J.R. and Rungruanganunt P. Accepted for publication. The International Journal of Maxillofacial Implants)

This ITI-sponsored study used a modified ISO protocol to test the performance of 4 different CAD/CAM abutments on Straumann implants. In this comparison, Nobel Biocare third-party abutments had highest resistance to failure and outperformed those of Glidewell, Astra, and Straumann. Importantly, the failure modes observed in the study mimicked those present in a real-life setting, indicating the clinical relevance of these findings. The 4 different abutment types look extremely similar upon clinical examination; however, they differ significantly in performance. The authors attribute these differences to the design and fabrication technique to conclude that "the manufacturer matters."

→ For availability see: *The International Journal of Oral and Maxillofacial Implants.*

Nick Holt: "Looking back, everything went so fast. I went in on the day of my treatment and left by the end of the day with fixed teeth that make it possible for me to eat and drink in confidence again. The impact on my life has been tremendous."

The Good Life: "I've regained my old smile!"

Nick Holt of London, England, lost all the teeth in his maxilla to chronic advanced periodontal disease. The All-on-4® treatment concept provided him with a fixed, affordable solution. His dentist used NobelGuide for planning and guided surgery, and he chose four NobelActive implants and a milled NobelProcera Implant Bar Overdenture in Nick's case.

By Nick Holt

I think I probably had my denture for two or three years—at least—before considering implants. I found myself taking out the denture every time I wanted to eat so I could taste the food. It wasn't a sustainable situation.

Before treatment, people often asked me to repeat whatever I had just said. I simply couldn't speak properly with a denture.

When my dentist first talked to me about implants, I had just a few teeth left in my lower jaw, and they were affected by gum disease. In the upper jaw, all I had was my broken-down denture. Essentially, I had just three teeth showing.

It didn't take more than a few minutes of conversation before it became obvious that there was no real alternative to implants.

The doctor and his staff stabilized the gum disease in the lower jaw and placed a fixed bridge on my remaining teeth. In the upper jaw, he used a Nobel Biocare protocol called the All-on-4® treatment concept.

1965 First for 50 years

It involved four implants placed in the minimal amount of bone I had remaining. The surgery was very straightforward—nothing complicated like bone grafting—and the results have been great.

I look the way I used to look, I've regained my old smile, and I can really taste the food again.

Tremendous impact

The dentures were never really a part of me, but my new teeth really feel as if they are my own.

Looking back, everything went so fast. I went in on the day of my treatment and left by the end of the day with fixed teeth that make it possible for me to eat and drink in confidence again. The impact on my life has been tremendous.

Although this treatment was more expensive than a new denture would have been, I have to say it was money well spent. My new teeth are nothing like my old denture. I simply don't notice them. Without question, I have seen a big change in my life as a result of this treatment.

"You look different!"

Somebody I hadn't seen for a while ran into me the other day and the first thing she said to me was: "Oh, you look different!"

As it happened, I had just had a haircut, so I thought to myself, *It must be the haircut!*

Before I could reply, however, she added, "It's your teeth—very nice indeed!"

Naturally, I feel far more confident meeting and talking with people today than I did before my treatment. I have a smile that I can be proud of, which means I can recommend the All-on-4® treatment concept wholeheartedly. <

→ More to explore!
If you would like to know more about the minimally invasive implant-based solution that includes a fixed full-arch restoration for high patient satisfaction, you can read more about the All-on-4® treatment concept at: nobelbiocare.com/all-on-4.

Adult Craniofacial Changes Over Time

The fourth dimension should be taken into consideration during 3-dimensional planning for implant restoration.

In this conversation between Dr. Richard Sullivan of Nobel Biocare and Dr. Oded Bahat of Beverly Hills, California, Dr. Bahat shares his insights about planning for dynamic physical change based upon the decades of patient follow-up of implant restorations that he has carried out.

A well-known clinician, Dr. Oded Bahat maintains a private practice limited to periodontics in Beverly Hills, California, USA. Not only a clinician, but also a popular international lecturer and a prolific writer, he has published over 30 scientific articles.

Dr. Richard Sullivan: You have always emphasized the importance of extra-oral and facial parameters in your pre-operative data gathering and treatment. Now this has expanded to an emphasis on adult craniofacial changes. Would you explain this progression?

Dr. Oded Bahat: To support a treatment plan that includes extensive reconstruction, analyzing the entire face is essential in my opinion. I can then determine the possibilities for future esthetics.

Intra-oral esthetics is a part of facial esthetics. What we observe in a face are convexities and reflected highlights. These contours allow us to determine shapes, space, distances. These parameters are different between a youthful and aged face. Contours of the lower third of the face are affected by the combination of both hard and soft tissue augmentation procedures as well as the dental reconstruction—the teeth themselves, the arch form, which affects lip support, and support of lower facial height structures.

Q&A

Questions and Answers

This analysis has always been based on conditions as they present, which is a moment in time. When planning for implants to support a restoration, we have always proceeded with the assumption of a more or less static relationship of implants relative to teeth in both the same arch and the opposing arch. Now we are more aware that this is not true in some cases. Neither the jaws nor the face as a whole are static.

Are these changes truly noticeable?

Bahat: For some individuals very noticeable, and in some situations, difficult to treat. The change can be subtle. For instance, dentists will sometimes have a patient mention that a space has opened between a tooth and an implant restoration. That is common. What brings it to their attention is food impaction that was not originally a problem.

Other people who have a maxillary implant restoration of single or multiple teeth may begin to notice that the implant restoration is becoming shorter relative to the incisal edges of the adjacent natural teeth, accompanied by asymmetry of the soft tissue.

What is actually occurring is that the teeth and soft tissue are moving down in a harmonious way, but the implant and its associated restoration are fixed in position. This results in thinning of the bone and soft tissue on the labial aspect of the implant.

What are some of the more severe cases you have seen?

Bahat: Severe vertical asymmetry is the most noticeable and difficult to treat. Replacing the crown for someone with a high smile line would result in a long tooth and obvious soft tissue asymmetry. We have seen this in men and women still in their 30s, people who had congenitally missing lateral incisors replaced with an implant-supported crown in their early 20s.

Dr. Oded Bahat and Richard Sullivan interrupted for a photo in their conversation about craniofacial changes in adults over time.

We have also seen people with larger implant restorations in one quadrant that do not keep pace, you might say, with the changes occurring with the jaw structures and teeth in the other three quadrants.

> *"Surgical reconstruction with implants today should anticipate the vectors of potential facial changes in the future."*
> — Dr. Oded Bahat

This causes significant changes in occlusion, placing the natural teeth at risk when the implant restoration is no longer able to support the occlusion as designed. In essence, the rest of the bone and teeth have moved away from the stationary implant restoration.

We are facing the result of continuous, physiologically normal changes and a stationary element. This means that the focus cannot be only on the implant restoration, as the effect of craniofacial changes could be most pronounced on the remaining dentition, remote from the implant site.

You mention a woman in her 20s—of an age where we don't ordinarily consider growth to be a risk factor. Is there an age at which we can expect this potential consequence to go away?

Bahat: What we have found is that the potential for craniofacial changes as described are lifelong. In women there is often an accelerated change, thus greater risk of disharmony occurring in the mid 40s and in men between 45 and 50. Both from our own observations and also as reported by Torsten Jemt, people treated in their 80s can still be affected by these changes in their 90s, so no age can be considered past the point of potential occurrence.

Knowing this information now, how has this affected your treatment planning and surgical approach?

Bahat: Reviewing forensic anthropology, facial plastic surgery and adult orthodontic studies, we know that when these changes occur, they are 3-dimensional, with multiple vectors. The magnitude and exact direction varies.

Facial morphology does yield some clues, which has affected my planning in several ways. One is that whenever possible the 3-dimensional positioning of the implant is placed as close as possible toward the likely direction of growth—and therefore away from potential future bone resorption—without compromising the final esthetic and restorative result. This reduces the short- and medium-term effect.

I also tend to choose the minimum diameter of implant suitable—from a biomechanical requirements point-of-view—for a specific site, and consider designs that are more easily retrievable should this become necessary in extreme cases.

Another factor I take into account is grafting, especially in the anterior esthetic areas. Now I am considering the incorporation of a non-resorbable layer of particulate graft on the facial aspect in addition to autogenous bone. Since the autogenous graft behaves as native bone, adding non-resorbable graft material will

continued on page 11

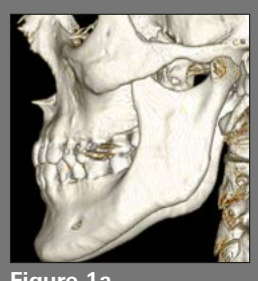

Figure 1a.

Figure 1b.

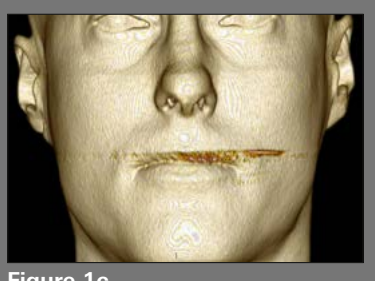

Figure 1c.

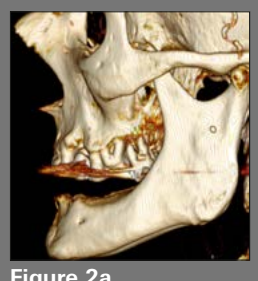

Figure 2a.

Figure 2b.

Figure 2c.

Figures 1 and 2. These figures are full head scans of two different men (taken for other medical indications) and used here to illustrate general craniofacial changes. Please note: There are variations gender-specific to women. The top row shows lateral and frontal skull views and formatting with facial features of a 36 year-old man. The bottom row shows corresponding views of an 89 year-old man. **Figure 2a** shows relative elongation of mandibular ramus and decrease of the mandibular angle. The anterior maxilla is vertical due to downward growth. **Figure 2b.** While direct comparison is not possible, the general thinning of bone is evident. **Figure 2c.** Overall loss of skeletal bone volume, fat volume and elasticity of the skin is evident.

Upcoming Events

Meet Nobel Biocare at events around the world. These professional gatherings provide a great opportunity for catching up with the latest innovations and scientific research.

2015

DGI – ÖGI – SGI Congress
November 26–28
Vienna, Austria

GNYD Annual Meeting
November 27 – December 2
New York City, NY, USA

AAOMS Dental Implant Conference
December 3–5
Chicago, IL, USA

2016

CIOSP Annual Meeting
January 27–30
São Paulo, Brazil

AEEDC Conference
February 2–4
Dubai, United Arab Emirates

AO Annual Meeting
February 17–20
San Diego, CA, USA

CDS Midwinter Meeting
February 25–27
Chicago, IL, USA

LMT Lab Day
February 26–27
Chicago, IL, USA

Expodental Conference
March 10–12
Madrid, Spain

Taipei City Dental Association
March 14–15
Taipei, Taiwan

Pacific Dental Conference
March 17–19
Vancouver, BC, Canada

ICOI World Congress
March 31 – April 2
Barcelona, Spain

IDEM Conference
April 8–10
Singapore, Republic of Singapore

Osteology Symposium
April 21–23
Monaco, France

SEPA Annual Meeting
May 12–14
Valencia, Spain

EAED Spring Meeting
June 2–4
Copenhagen, Denmark

Nobel Biocare Global Symposium 2016
June 23–26
New York City, NY, USA

→ More to explore
For the most recent updates, visit: nobelbiocare.com/events

For A Healthy Start, Always Use a New Healing Abutment

Material in contact with the soft tissues affects the quality of the mucosal attachment.

Healing of the soft tissue in the oral cavity has been under thoughtful study recently. In the article below, the authors explain the significant influence the healing abutment has on that process.

By Dr. Chandur Wadhwani and Steve Hurson

The healing cap protects the internal aspects of the implant from debris accumulations and serves as the initial transmucosal connection between the external environment and the inner parts of the human body.

As a bacteriological barrier with a tight connection between the epithelium and implant component, it helps to prevent infection, crestal bone loss and soft tissue recession, all of which are crucial for long term success.

Two-zone barrier

The soft tissue barrier that contacts the standard titanium healing abutment consists of two zones: a marginal zone consisting of junctional epithelium and a deeper apical zone comprised of a fiber-rich connective tissue.

It has been shown that the properties of the material placed in contact with the soft tissues have a decisive influence on the quality of the mucosal attachment. Chemical composition and surface topography of the abutment material play a role in tissue recession and prevention of crestal bone loss. The ability of the cells to attach and spread is dependent upon surface hydrophilicity (wettability) and "lack" of surface contamination.

Figure 2. The screw thread may contain bio-burden after it has been removed.

Figure 1. Healing abutment (left) was placed in an Ultrasonic bath for ten minutes, then autoclaved. However, since proper cleaning was not achieved, sterilization was not possible. Compare this to a new healing abutment (right) and the difference is obvious!

Although designed and labeled *for single use,* some clinicians advocate re-using—or "recycling"—healing abutments from one patient to the next for purely economic reasons. A breach of manufacturer guidelines, this is not a wise choice.

Five reasons why healing abutments are for single use only

1. According to Nobel Biocare guidelines, the company's healing abutments should each only be used once.

The argument against re-using a healing abutment is evident in the images above (Fig 1). No matter the method used—steam or chemical autoclave, ultra-violet light, or ethylene oxide—sterilization can never completely recreate the pristine surface of the original abutment.

2. Re-using a healing abutment labeled for single use may seriously degrade the performance of the product. Sterilization with a steam autoclave, chemical autoclave, lasers or ethylene oxide may alter the composition of the titanium surface, negatively affecting cells.

Physical surface topography changes the titanium wettability, which interferes with the epithelium and fibroblast cells' ability to attach and spread. This effect is quite different from that of a new (i.e. not previously used) healing abutment.

3. New screw threads are vital for consistently favorable results.

The screw thread component of the healing abutment may also contain bio-burden after it has been removed, and a screw thread is by far the most difficult part of the healing abutment to clean (Fig. 2).

Although not in direct contact with healing tissue, studies have confirmed contamination and wear affect the screw thread and may result in damage within the implant.

Contamination can also lead to healing abutments "locking" onto the implant. This is an extreme issue and has been known to result in the implant being reverse-torqued out of the bone in attempts to unscrew the abutment.

4. The screwdriver may not properly engage a re-used healing abutment.

Very difficult-to-remove debris (Fig 3) may clog the screw driver insertion site. It should be noted that ultrasonic baths are not likely to get rid of this tightly packed material. Also, with repeated use, the screw head itself can become mechanically damaged. Case reports in the literature report that such damage—unnecessary if you follow the manufacturer's single-use guidelines—makes healing abutment retrieval problematic (Fig. 4).

5. Mechanical cleaning of a previously used abutment—especially via air particle abrasion—can damage the abutment/implant connection, thus reducing its sealing capacity and altering the component connection (Fig. 5 A&B). Studies have also reported abrasive impregnation into the softer titanium, resulting in metal contamination.

A potentially costly risk

Take these five points under careful consideration and you will find that the potential monetary savings of re-using a healing abutment a second time do not outweigh the known and potential health risks to the patient.

In short: in order to provide patients with the greatest chance of soft tissue attachment, minimized inflammation and the prevention of possible recession—and to give the bone a healthy start—*always use a clean new healing abutment!* <

→ More to explore!
Full references for this article are available online at:
nobelbiocare.com/news



Figure 3. Debris often packs very tightly into the area of the screw head. Physical removal is often achieved at the expense of damage to the site.

Figure 4. Repeated use of the star driver has rounded the engaging part of the screw.





Figure 5. Scanning electron microscopy images of conical connection at 500x magnification (A – to the left). The effect of air particle abrasion cleaning on the fitting surface of an implant abutment is clearly evident (B – to the right). The implant-abutment interface with a new, clean abutment surface for comparison.

Digital Precision for All Indications

NobelGuide® is a complete treatment concept for diagnostics, treatment planning and guided implant surgery.

For 10 years and counting, NobelGuide has been a leader in guided surgery for clinicians seeking peace of mind through increased treatment predictability.

By Jim Mack

Beginning with the initial diagnosis and moving to the first guided drill, whether edentulous or not, NobelGuide supports clinicians from beginning to end. And with more than 40 publications assessing its clinical application, NobelGuide has been documented in more than 950 patients with over 5900 Nobel Biocare implants.

As a complete treatment concept for diagnostics, treatment planning and guided implant surgery, NobelGuide helps to diagnose, plan the treatment and place implants based on restorative needs and surgical requirements.

Diagnose and plan

NobelGuide is powered by the NobelClinician Software which helps provide a complete anatomical picture by assessing detailed 3D patient scans. Implant placement is easily visualized on screen where the clinician can take into account important factors such as the availability of bone and prosthetic needs.

With NobelGuide, clinicians can choose to complete the whole surgery fully guided, or to use a surgical template just for pilot drilling. The range of pilot drill surgical templates has been extended to cover both partially edentulous and edentulous cases.

A new edentulous option

New pilot drill templates can now be used for the All-on-4® treatment concept, helping to ensure accuracy every time by simply guiding the initial drill according to your NobelClinician treatment plan.

For edentulous patients the workflow includes the radiographic guide with a double-scan protocol. After the clinical diagnosis, the diagnostic tooth setup is fabricated and validated before being transformed into a radiographic guide.

After (CB)CT scans of the patient and radiographic guide, the implant position is defined and the individualized surgical template is ordered and everything is ready for surgery. <

A seamless workflow for every case

Every case you have is different – from a single missing tooth to an edentulous jaw. That's why NobelGuide offers you a choice of treatment workflows for either the partially edentulous or the edentulous.

EDENTULOUS

1 CLINICAL DIAGNOSTICS

Examine the patient. Take an impression for study models and, later, the master cast.

2 DIAGNOSTIC TOOTH SETUP AND FABRICATION OF RADIOGRAPHIC GUIDE

Fabricate and clinically validate the diagnostic tooth setup. Transform the tooth setup into a radiographic guide – your prosthetic reference during planning.

3 DIGITIZATION WITH (CB)CT SCAN

Make a (CB)CT scan of the patient and the radiographic guide following the double-scan protocol.

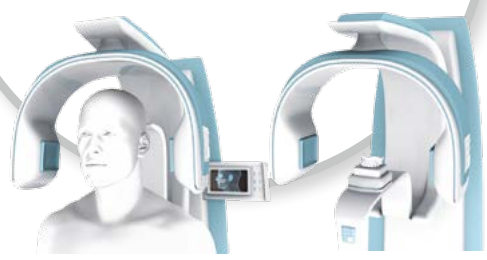

PARTIALLY EDENTULOUS

1 CLINICAL DIAGNOSTICS AND TREATMENT ACCEPTANCE

During diagnosis, identify critical anatomical structures with the NobelClinician Software. Take a definitive impression. Obtain treatment acceptance before making further investments. A (CB) CT scan can be taken at the first visit with no need to use a radiographic guide.

2 DIGITIZING PROSTHETIC INFORMATION

Collaborate with your lab technician and capture the soft tissue using the NobelProcera 2G System's precise model scan. Choose whether to include the diagnostic tooth setup.

3 3D DIAGNOSTICS, TREATMENT PLANNING AND COMMUNICATION

Visualize the patient's (CB)CT data together with the intra-oral situation, including soft tissue and the diagnostic setup, when you use NobelClinician's SmartFusion technology. Effectively communicate the treatment plan to your patients using the Communicator iPad® app.

10 years NobelGuide® consistent precision

Key findings

- **Higher accuracy and predictability of implant positions, in comparison with freehand surgery.[1]**
- **Excellent cumulative implant survival rates (CSR) of 96.8% weighted mean in 38 studies with guided surgery technique in up to seven years of follow-up.[2]**
- **Significantly lower swelling, edema and pain[3,4], as well as reduced use of analgesics[3,4,5] with guided flapless surgery, compared with freehand surgery.**
- **Very high subjective patient satisfaction[3,6,7] and high average scores of 99.2 for masticatory function and 98.1 for esthetics as assessed by Visual Analogue Scale (1:100).[8]**

[1] Tahmaseb et al. Int J Oral Maxillofac Implants 2014; [2] Nobel Biocare Services AG GMT79393. Science First 2015; [3] Pozzi et al. Eur J Oral Implantol 2014; [4] Nkenke et al. Clin Oral Implants Res 2007; [5] Bertossi et al. Minerva Stomatol 2013; [6] Puig et al. Eur J Oral Implantol 2010; [7] Meloni et al. Eur J Oral Implantol 2010; [8] Pozzi et al. Clin Implant Dent Relat Res 2015.

4

3D DIAGNOSTICS, TREATMENT PLANNING AND PATIENT COMMUNICATION

Define implant positions from a clinical, anatomical and prosthetic perspective by combining tooth setup with patient anatomy.

Right from the start

Guided pilot drilling assists you in achieving the correct angulation, direction and depth of the first drill when placing implants in narrow spaces or close to the inferior alveolar nerve. (Case courtesy of Prof. Alessandro Pozzi, Italy)

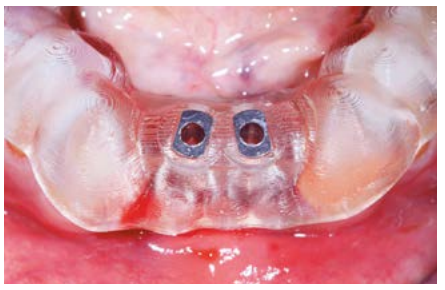

Edentulous treatment starts here

Confidently make use of all available bone and overcome challenges such as bone resorption and avoid critical anatomical structures.



Accuracy and predictability

Using the individualized surgical templates turns your treatment plan into clinical reality. Choose between guided pilot drilling with the first drill or fully guided implant insertion.

Visualization of patient's anatomic structures and diagnostic wax-up using the SmartFusion. Virtual placement of NobelActive NP for the lateral incisors and NobelActive RP for the central incisors.

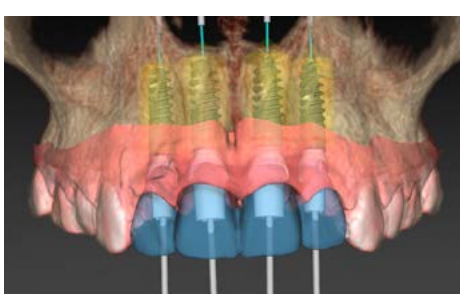

The surgical template was seated immediately after atraumatic tooth extraction. Implants were placed using a fully guided surgical template. (Case courtesy of Dr. Peter Wöhrle, USA.)

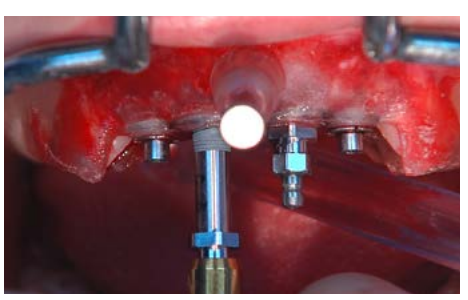

FIND OUT MORE

View the complete NobelGuide offering. Scan the QR or visit: bit.ly/nobelguide

Seeing the Treatment Through to Success

Proper oral hygiene and post-treatment care are essential for the best long-term outcomes.

Proper maintenance care is an integral part of achieving success with every dental implant treatment.

By Dr. Paul S. Rosen

Dental implants have a well-documented history of high success and survival rates. In fact, implants have in many instances become the "go to" treatment option when a tooth, or teeth, are experiencing problems that deem them hopeless.

Nevertheless, complications can occur that can be either biologic or mechanical. The vast majority of dental implant problems, experienced during the maintenance phase of care, are related to inflammation.

If the clinician is better able to identify and understand this, prevention and management can be performed more effectively. The importance of more stringent follow-up care for dental implants versus teeth is something that is oftentimes unrecognized and understated. Unfortunately, many patients have the erroneous belief that implants are immune to complications.

The two major biologic complications encountered during the maintenance phase of care for dental implants are peri-implant mucositis and peri-implantitis. The former condition is one in which the inflammatory lesion is contained within the soft tissues surrounding the dental implant, and is not associated with crestal bone loss beyond that seen with physiologic modeling or remodeling of the hard tissues that occurs following implant placement and loading (Figures 1 & 2).

While this clinical condition has been called mucositis, it may be misleading because this inflammation can be present both in the presence and absence of keratinized tissue, i.e. gingiva.

Peri-implantitis is often defined as the condition where bone has been lost around the dental implant due to the pathologic progression of inflammation (Figures 3 & 4).

It can threaten the survival of dental implants. It is of the utmost importance to distinguish between bone loss on the implant that is related to disease, as opposed to that associated with physiologic modeling/remodeling.

S&E

Safety and Efficacy

In order to determine if complications are beginning to occur, so that they may be intercepted at as early a moment as possible, it is important for the periodontist and restorative dentist to:

- Identify risk factors associated with developing peri-implant diseases,
- Establish a radiographic baseline at the time of implant placement,
- Establish a clinical and radiographic baseline at final prosthesis insertion, which includes periodontal probing where possible (Figure 5),
- Design a tailored maintenance program that employs methods such as periodontal probing (wherever possible) that not only aids the patient in his or her hygiene efforts, but also monitors the stability of implant health and determines if inflammatory complications are beginning to occur, and
- Establish an early diagnosis and intervention, which will contribute to more effective management of peri-implant diseases.

Figure 5: Probing of the implant.

Figure 6: Interdental cleaning with a Proxabrush®.

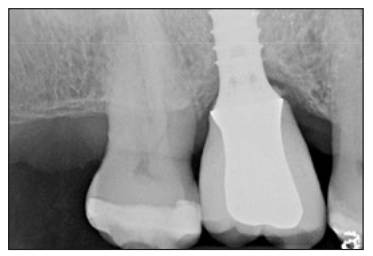

Figure 7: Excess cement.

Figure 8: Purulence associated with cement.

Figure 9: Mechanical removal of cement using a scaler.

Figure 10: Nd:YAG laser being used to treat peri-implant mucositis.

The question arises: What are some of the inflammatory risk factors about which we must be aware?

From past and emerging evidence, smoking, uncontrolled diabetes, a history of periodontitis, and even a history of cardiovascular disease present an "inflammatory dysbalance" to the steady state around an implant.

For patients with these factors noted in their medical or dental history, maintenance on an annual or even a semi-annual basis may not be enough. These patients may need to be seen at a more frequent interval, such as every 3–4 months to maintain a steady state of health.

So, will standard brushing and flossing on the part of the patient along with the use of traditional hygiene instruments manage these problems? In some instances, yes, but not in every case.

Maintaining the peri-implant tissues in health is the responsibility of both the patient and the dental team (hygienist, restorative dentist, periodontist). Preventing the recurrence of inflammatory diseases involves ongoing plaque control and, where necessary, treatment that establishes a local environment to support this control.

Initially, the patient's plaque control techniques must be observed and possibly modified to a level deemed effective. When they are not, it must be determined whether these efforts fall short due to suboptimal effort on the part of the patient or less than ideal implant positioning due to ridge position or prior bone loss, where pink restorative materials may be needed to facilitate the esthetics, phonetics and function.

In these instances, adjunctive devices for homecare such as a Proxabrush® (Figure 6) (Sunstar Americas, Schaumberg, Illinois), an end-tufted brush, or a Waterpik® (Water Pik, Inc. Fort Collins, Colorado) may need to be considered whenever traditional brushing and flossing fall short of total plaque removal.

Moreover, antimicrobial rinses may also be necessary to reduce the bioburden that may develop and in some instances, it may be essential that the prosthesis be removed on a regular basis when the patient comes in for their maintenance visits.

For the treating hygienist, what tools are needed in the armamentarium to manage the peri-implant region?

Debridement of the implant-supported restoration must be directed at three components: the prosthesis, the abutment, and the implant fixture, should its surface become exposed to the oral cavity. The restoration can be debrided, as with any other prosthesis, using appropriate instrumentation that avoids damaging the restorative material.

The restoration needs to be instrumented to remove any accumulated plaque and calculus biofilm or residual cement (Figures 7–9) while avoiding damage to the integrity of its smooth convex surface. No one approach accomplishes this goal in all situations and each scenario may require a customized approach to achieving a plaque- and calculus-free environment.

Utilizing conventional metal instruments designed for the natural dentition have been called into question as they have been shown to damage the implant abutment's surface. Alternative options, depending on manufacturer guidelines, may involve air powder abrasion, specially designed sonic or ultrasonic instruments with padded tips; titanium and non-metal instruments manufactured for implant use; or perhaps dental lasers of specific wavelength(s) (Figure 10).

Non-metal instruments have demonstrated minimal or no damage to both machined and rough titanium surfaces with good adaptation to abutment surfaces. However, while plastic-coated scalers may cause minimal damage and may also have a polishing action, they can leave residual plastic deposits on the implant surface.

Moreover, some of these instruments are too thick to gain access to areas requiring debridement. The take-home message is that no two implant prostheses are exactly alike and one needs to have a variety of instruments at her or his disposal to maintain a steady state of health.

In summary, ensuring the long-term health of the dental implant is a team effort that includes coordination from the outset of care. If everyone plays his or her role in this enterprise, dental implants can maintain a healthy and highly satisfactory treatment that meets the patient's goals. <

Figures 1 & 2: Peri-implant mucositis 3.5 years after implant placement.

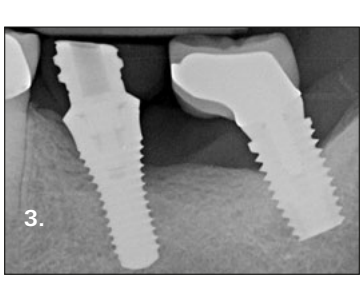

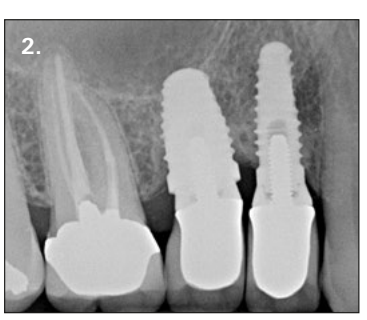

Figures 3 & 4: Peri-implantitis.

→ More to explore!
Full references for this article are available online at: nobelbiocare.com/news.

Taking the Laboratory into the Future

"A system that works together means there are no surprises as you progress with the case."

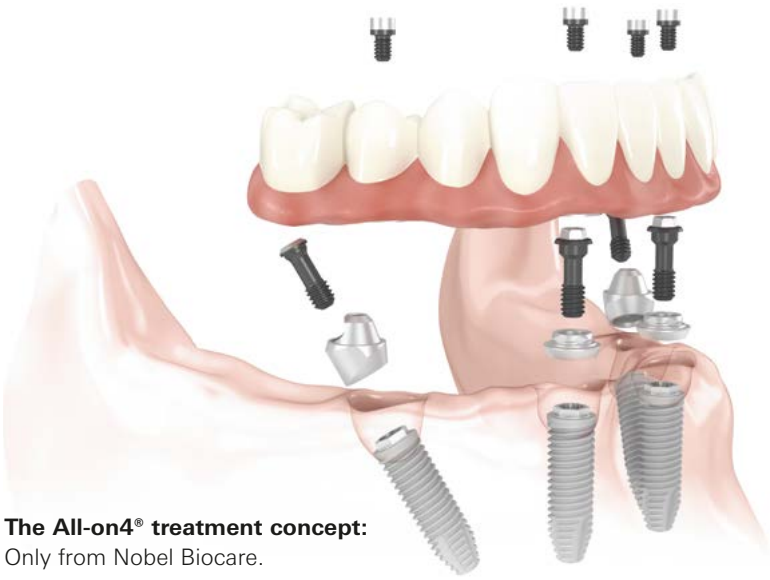

The All-on4® treatment concept: Only from Nobel Biocare.

Marotta Dental Studio in Farmingdale, New York, is one of the United States' premier dental labs. Employing highly skilled dental technicians, they emphasize service, support and education as the basis for their quality work. Not surprisingly, they promote the All-on-4® treatment concept. We have spoken with two of the company's leaders.

Steven Pigliacelli, CDT, MDT, and Dr. Leonard Marotta are two of the three principles of Marotta Dental Studio. An erudite dental technician and engineer, Marotta earned his PhD in Biomedical Engineering from Leeds Metropolitan University in the UK. Pigliacelli has more than 30 years' experience at Marotta Dental Studio as a dental implant specialist and holds a Master of Dental Technology from NYU.

How did you get started with All-on-4® treatment concept cases?

Steven Pigliacelli: We have been making hybrid cases for over 30 years and receiving milled titanium Procera frames from Nobel Biocare since the early 90s. We were the beta lab for the original Procera implant bridge, which was called the All-in-one Bridge. So for us to make the transition to a milled titanium hybrid solution on four implants was an easy and natural one.

Lenny Marotta: Back in the 1990s, I started doing All-on-4® cases with Nobel Biocare as a continuation of our studies with Drs. Steve Parel and Steve Lewis, and we've done the All-on-4® treatment concept ever since.

What do you see as the key benefits of handling All-on-4® treatment concept cases for a lab?

Pigliacelli: For the lab and doctor, a key benefit is having a standard denture and implant protocol. We have a detailed protocol at the lab that has served us well for many years. Every step is discussed with the doctor, supported by instructional memos and chairside consultation, if needed. This ensures that there are no complications, and everything goes smoothly.

You have been working with NobelProcera titanium frameworks for a long time. What are the main advantages of titanium, particularly for substructures for the All-on-4® treatment concept?

Marotta: The NobelProcera Titanium frames always come back with a precise and accurate fit. This is particularly important for All-on-4® cases, since no adjustment is needed and no undue stress is put on the implants.

Pigliacelli: A milled titanium frame avoids distortion issues in the interface that happen during a casting process. Once the gold cylinder is placed in an oven, it distorts, then when the alloy melds to it, it distorts again.

Soldering, when necessary, is another source of distortion and a possible source of breakage and porosity. Because the milled titanium frame is a solid one-piece milled bridge, the need for solder connections is completely eliminated.

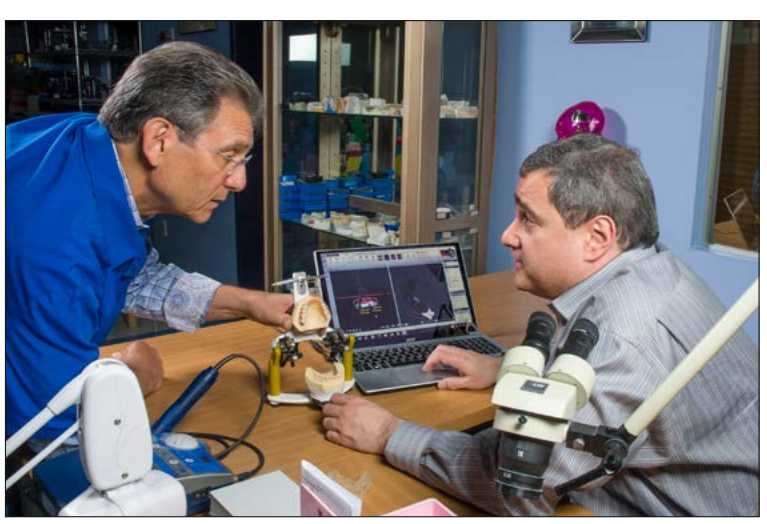

Lenny Marotta and Steven Pigliacelli personify hands-on leadership as the top managers of Marotta Dental Studio on Long Island, New York.

Q&A

Questions and Answers

And how about zirconia? Is this a material you are working with more frequently? What do you see as its advantages?

Marotta: We have worked with zirconia for crown and bridge restorations for many years. It has very high strength and works well when there is limited occlusal space and esthetics are a concern.

Pigliacelli: Zirconia certainly has its place in the industry. We have done crowns, implant frames and full contour bridges. It is not the savior of the dental industry, however. There are limitations to case design and viability. There are years of research on implant restorations and the All-on-4® treatment concept; yet not on full-contour zirconia restorations.

Nowadays we hear a lot more about the benefits of the team approach—labs, restorative dentists, surgeons and the industry all working together to help ensure the best possible results for patients. Do you see this as an opportunity for labs like yours?

Marotta: The team approach is nothing new for us at Marotta Dental Studio. We have always worked closely with every member of the team, be it the restorative dentist, oral surgeon, orthodontist, periodontist or radiologist. From the very start, we have worked closely to ensure the best possible results for patients.

Pigliacelli: And we have lectured extensively on the team approach for years. Our relationship with our accounts is one of camaraderie and friendship. We stay away from the adversarial relationship that many dentists and labs have. We work side-by-side in fabricating everything from complex implant bridges and all-ceramic esthetic restorations to a simple crown and bridge.

"We at Marotta Dental Studio have always worked closely with every member of the team," says Lenny Marotta (right). "Our relationship with our accounts is one of camaraderie and friendship," adds Steven Pigliacelli (left). Solid teamwork, they both agree, lies at the heart of All-on-4® treatment concept success.

Clinicians are beginning to see the benefits of involving labs earlier in the treatment process. The labs' value to the clinician often increases when they have knowledge of digital planning software. You use NobelClinician. How has incorporating this digital tool into your offering helped your lab?

Marotta: We have worked with NobelClinician from the start. We have it available at our lab for doctors to use on their own or as part of a digital planning session. Guided surgery is appropriate for a variety of situations. Today we can plan a case with our accounts to ensure that the implants will be placed where they will provide the best support for the restoration.

Pigliacelli: Guided surgery is one of the most important advances in the industry. NobelClinician ensures that the case at hand can be completed as a screw-retained bridge, such as in the All-on-4® protocol. Gone are the days of having a misplaced implant because "that's where the bone is."

There are lots of All-on-4® look-alikes out there, what do you believe are the benefits of using the original, proven treatment concept?

Marotta: Nobel Biocare's All-on-4® research dates back to the 1990s. There are ample clinical studies backed up by years of research and data that support the viability of the system. Look-alikes can't possibly match that history ...

Pigliacelli: ... and therefore may not work as well as the original!

The All-on-4® treatment concept comprises several key elements: the implant, the abutment, the restoration and the detailed protocol. How would you summarize the advantages of using components that are engineered to work together as one system?

Pigliacelli: Having a system that works together, backed up by a protocol for all steps, means there are no surprises as you progress with the case. From the start we know exactly what components and parts we need, and can plan for contingencies with a system that is designed to work together. This greatly enhances treatment efficiency, and patient satisfaction.

Marotta: Using components that are all part of a unified system provides the best possible results for our accounts and patients. We know going into a case what will be needed to achieve the desired results. All the years of research support not just one aspect of the system but all the features—as one unified restorative system.

This allows for immediate implant loading, shorter treatment time, enhanced esthetics and function, increased patient satisfaction and reduced overall cost. Nobel Biocare / NobelProcera provides the best and most accurate results when utilizing four implants. <

→ More to explore!
For further reading, please visit us at:
nobelbiocare.com/all-on-4

Solve Four Common Posterior-region Challenges

Nobel Biocare brings innovative technology to the posterior region.

Restoring single molars is a common indication for most clinicians placing implants, but that doesn't mean it's straightforward. Here we look at how to overcome four challenges frequently encountered in the posterior region.

By Michael Stuart

The Omnigrip Screwdriver is designed for a strong grip on the screw in order to limit the risk of it detatching in the patient's mouth.

If you're taking an immediate placement approach, then large molar extraction sockets can make it difficult to achieve sufficient stability.

Large molar sites

The need for a large molar crown means that additional considerations have to be taken when it comes to the emergence profile.

Restorations that are significantly wider than the implant platform could, at best, leave space where food can become trapped. At worst, they could be detrimental to the marginal bone. In both eventualities, you may have patients coming back with complaints.

To try to help avoid these issues, you can use wide-platform implants, such as those found in the NobelActive and NobelParallel Conical Connection systems. You can also further improve the emergence profile by using healing and temporary abutments designed specifically for the molar region.

Limited accessibility

The reduced space and light in the posterior region can make placing the restoration tricky. And working at the back of the mouth means there's a high risk of the patient aspirating any small components that can come loose.

Improve accessibility by selecting an abutment with an angulated screw channel. Being able to position the screw access hole towards the lingual or mesial aspects makes it easier to reach. The right tooling can also improve handling. Nobel Biocare's unique Omnigrip Screwdriver is designed for a strong grip on the screw to limit the chances of it detaching in the patient's mouth. This offers a little extra peace of mind, particularly when you're working in the posterior.

Excess cement

Case studies have indicated that excess cement can have a detrimental effect on peri-implant tissue health. Despite the risks, a survey of 400 dentists by Wadhwani and Piñeyro (Int J Oral Maxillofacial Implants 2012) found that some place up to twenty times more cement than they need.

An overload of this scale means that up to 95% of the cement that's placed extrudes at the restorative margin. With the restorative margin often below the gumline, this can pose real problems, particularly in the molar region, where accessibility and visibility make removal of cement especially difficult.

You can avoid this issue entirely by using a screw-retained restoration like the NobelProcera FCZ (full-contour zirconia) Implant Crown. As even the adapter is mechanically retained, the restoration is completely cement-free.

Alternatively, Wadhwani and Piñeyro suggest a technique for minimizing excess cement by creating a chairside copy abutment that serves as a controlled applicator for the cement.

High occlusal forces

If your restorations are going to withstand the high occlusal forces experienced at molar teeth, they need to be strong. Those created specifically for the posterior region, like the NobelProcera FCZ Implant Crown, are designed to handle these demanding conditions in the long term.

High forces can also lead to veneer chipping. As the NobelProcera FCZ Implant Crown is a monolithic full-contour option, it overcomes this challenge too, as no veneering is required.

Four problems, one complete solution

To overcome all these challenges, we're bringing innovation back to the posterior region. Our new complete posterior solution combines wide-platform NobelActive and NobelParallel CC implants with anatomically shaped PEEK Temporary and Healing Abutments.

Then, for the final restoration there's the high-strength, cement-free FCZ Implant Crown with the option for an angulated screw channel. In combination, these innovations are designed to make your life easier when restoring molar teeth. <

→ More to explore!
Full references for this article are available online at: nobelbiocare.com/news.

The NobelProcera FCZ Implant Crown combines full-contour strength with restorative flexibility, whichever of the eight shades you choose.

In Brief

Set up your practice for success

NobelClinician is now available in a new format that comprises a multi-license package, which can be tailored to your specific needs.

In order to make your practice more efficient and successful, Nobel Biocare is now delivering the NobelClinician Practice Setup. Whether you work in a small or a large clinic, have your own (CB)CT scanner or simply want to improve collaboration between team members, this package sets your practice up for success.

The software can be adapted to your specific needs, so you get the solution that works best for your practice. The entire team can now access NobelClinician at any computer in the clinic or remotely via NobelConnect, giving them the virtual tools they need to support treatment. What's more, with this setup, all NobelClinician data is automatically stored in one location, making it easy to back up.

→ For more information: nobelbiocare.com/practicesetup

Brånemark Memorial Symposium

In a fitting final salute to the father of osseointegration, researchers and clinicians from all over the globe gathered at the end of September at *Karolinska Institutet* in Stockholm, Sweden, to honor Professor Per-Ingvar Brånemark.

The P-I Brånemark Memorial Symposium not only chronicled the genesis of osseointegration, it also provided an enticing glimpse into the future of implant-related treatment.

Speakers at the gala dinner preceding the symposium returned again and again to Brånemark's many philanthropic activities, not least of all his clinic in Bauru, Brazil. Many an accident or cancer survivor has received a new lease on life thanks to the P-I Brånemark Institute there. It has become a world reference organization for osseointegration R&D as it applies to extra-oral, intra-oral and amputee rehabilitation. To learn more about its work and what you can do to help, please visit the website below.

→ For more information: branemark.org.br

Professional education at your fingertips

Find your next development opportunity whenever and wherever it suits you with the new Nobel Biocare Global Courses application. This new app allows you to quickly sort by topic, location or level depending on your learning objectives. You can also view profiles of our expert speakers who lead the training.

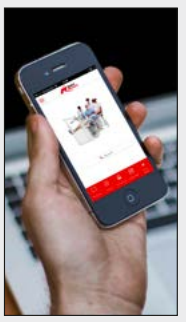

Found the course for you? Simply send a request for more info, mark it as a favorite or add it to your calendar, all direct from the app.

According to Dr. Chandur Wadhwani, it's essential to understand the very latest treatments and techniques. "The new training app is a great tool," he says, "and should be used by anyone dedicated to implant dentistry."

Scan the QR-code above for all the details!

→ Download the app today: bit.ly/NB-course-app

GBR Expert Looks at the Big Picture – First Class Handling is Only One Part of the Story

The dense mesh of creos™ xenoprotect holds the bone graft material securely in place for undisturbed healing.

Having lectured and co-authored papers and a textbook on the topic, Dr. Hadi Antoun of Paris, France, is an authority on guided bone regeneration (GBR) procedures. After introducing the creos xenoprotect resorbable collagen membrane into his practice, Dr. Antoun was kind enough to share his experiences with *Nobel Biocare News*.

A resorbable collagen membrane with outstanding handling properties and an extended barrier function, creos xenoprotect is a non-chemically cross-linked membrane for guided bone regeneration (GBR) and guided tissue regeneration (GTR) procedures.

What was your initial reaction, the first time that you used the creos xenoprotect membrane?

Dr. Hadi Antoun: That the membrane is easy to handle and, once moistened, does not stick to the site, so you can still change its position after placement.

Dr. Hadi Antoun says that creos xenoprotect provides advantages ranging from good handling to slow resorption.

Why is it so important to have a membrane that is easy to handle?

Antoun: During surgery we cannot afford to spend too much time adapting the membrane to the defect of each individual patient. We need a membrane that we can handle and cut easily, that does not stick to instruments and that can be adapted to the shape of the site after the biomaterial has been placed. Handling properties are important, but good handling alone is not enough.

What then have you found to be the other main advantages of creos xenoprotect?

Antoun: Its elasticity and high biocompatibility. Biocompatibility is fundamental, while the elasticity means it can be sutured or fixated with pins and then tightened without tearing. It also resorbs slowly, allowing time for the invasion of bone cells at the site, remodeling and bone regeneration.

In the case you are sharing with our readers online (see the link at the end of this article), you use a combination of xenograft substitute and autogenous bone. What benefits does this combination offer?

Antoun: The cells that survive transplantation in the autogenous graft provide osteogenic potential and growth factors that are released gradually. This compliments the bovine hydroxyapatite, which is a biomaterial that resorbs very slowly. It acts as a scaffold for bone regeneration, providing the augmented bone with stability.

You stated that in this particular case some remnants of the creos xenoprotect membrane could still be seen after six months. Were you surprised by this longevity?

Antoun: I was pleasantly surprised. Most resorbable membranes resorb after a few weeks or three to four months at most. The core principles of guided bone regeneration dictate that the longer we keep soft tissues and fibroblasts away from the bone area, the greater the opportunity for new bone to form. As such, a long degradation time like this provides a greater chance of success.

You chose to restore the case in question with a NobelProcera Titanium Abutment. Why did you opt for a NobelProcera individualized restoration?

Antoun: An individualized abutment with a scalloped contour, in a biocompatible material like titanium, is important for the attachment and adhesion of hemidesmosomes in the transmucosal part of the restoration. Bone preservation is very probably related to this barrier. Moreover, from an economical point of view, we don't have to deal with any additional costs related to a metal cast.

Were you pleased with the results of this case? What was the patient's reaction?

Antoun: Re-entry at six months was very satisfying. Bone augmentation covered all exposed threads, and the most interesting point was the bulky bone augmentation right up to the implant neck. There was more than 2 mm of newly formed bone on the buccal side.

What would you say to a clinician who is considering trying creos xenoprotect for the first time?

Antoun: I would recommend trying the membrane. The results are very encouraging and, provided that the basic principles of GBR are followed, complications seem very rare.

For me, the combination of autogenous and xenogeneic biomaterials with the membrane has worked well. The final trimming of the membrane can be done after the augmentation by stretching the membrane before fixating it. Tension-free soft tissue coverage is a key factor for successful bone augmentation. <

→ More to explore!
nobelbiocare.com/xenoprotect

The case referred to in this article is available at: bit.ly/creos-antoun

Craniofacial Changes Over Time

→ continued from page 4

create scar-like tissue and will camouflage or hide the grayish appearance due to tissue thinning facial to the implant.

For prospective patients, they are informed about this possibility and considerations that will be taken on their behalf prior to treatment. This is not really a complication of the implant or the restoration. It is rather a normal physiologic phenomena of the aging face and skull.

What advice would you give our readers based on your findings?

Bahat: I can only speak for the partially edentulous jaws as well as asymmetrical implant placement.

For patients already treated, understand that we cannot see or measure the changes occurring, we can only see the effects. Most importantly, when implants and teeth are within the same arch, occlusion must be checked routinely for unequal or unfavorable changes that dictate some corrective action.

If changes do occur in contacts or tooth length that necessitate replacement of the restoration, advise the patient that this may still occur again—in essence their face is "still growing."

Using a screw-retained replacement whenever possible will facilitate future restorative treatment. If you have a patient with high esthetic expectations and a high smile line, understand they are at higher risk because vertical discrepancy cannot be resolved by just replacing a crown.

For patients still to be treated, learn more about and anticipate the potential vectors of future changes and, without other compromises, incorporate this information into augmentation procedures, 3-dimensional implant positioning and restorative designs. Emphasize for every patient and co-treating dentist the necessity of routine occlusal assessment and arch integrity to protect the patient from changes before they become harmful. <

→ More to explore
For further reading and references, please visit: nobelbiocare.com/news

Taking Life at More Than Face Value

The face can express who we are as well as what we mean to say.

A member of the scientific committee for the upcoming Nobel Biocare Global Symposium 2016 and a professor in the Department of Surgery at Stanford University, Dr. Helms carries out research in the field of regenerative medicine, collaborating with experts in bioengineering, materials science, physics, and with colleagues in the life sciences. In this article, she explains why reconstructive craniofacial surgery can be decisive for the well-being of a deformed or injured patient.

By Professor Jill A. Helms

We come into this world primed to connect with the faces around us. This ability is literally hardwired into our neural circuitry. There is a specialized region in our brain, located in the temporal lobe in a region called the fusiform gyrus, which is filled with neurons that preferentially fire whenever a face comes into view.

Within minutes of birth, babies are using this brain region; studies demonstrate that even very young infants show a strong preference for looking at faces over all other objects.

The brain is responsible for coordinating every single activity that keeps you alive; and some terribly precious real estate in the brain is allocated to a pint-sized structure whose only apparent purpose is to become activated in response to a face.

Since evolution is constantly shaping the brain and adapting its function to ensure our survival, the fact that a brain region is dedicated to this task indicates that facial recognition must be essential for our survival.

But why?

One reason is because the face is the means by which we communicate. Thirteen years after "the origin of species" was published, Charles Darwin addressed this very question in a book entitled *The Expression of the Emotions in Man and Animals*. In this work Darwin wrote, "The welfare of mankind depends on the expression and recognition of emotion."

And if you don't believe Darwin, then witness any adult with an infant. Of all the motor skills that infants must master, none is as important as mimicking the facial gestures of people around them. Even at a very early age, humans devote a great deal of attention and energy to teaching infants the movements required for facial expression. In fact, we know that children who are incapable or uninterested in learning this task are often later diagnosed with conditions such as autism.

This focus on the face ultimately translates into our faces becoming central to our sense of identity. One doesn't need to look much further than children's drawings to see this. Ask a five year old to draw a human being and you'll get a stick figure with a lollipop-sized head, complete with a face. The face defines the entity.

Illustrators of children's books exploit this very characteristic: everything of emotional importance to a child is illustrated with a face. The sun has a face. The moon has a face. Thomas the train has a face. It's a way to personalize the world.

Beauty, a sign of well-being

The face is not only important as a means to communicate; the face also serves as an advertisement for our health, youth and vitality. A face that projects an image of great health indicates a good choice for a mate.

Across all ethnic groups and epochs, the general hallmarks of beauty have been symmetry and a balance in proportions. Surprisingly perhaps, people universally agree that the most beautiful faces are actually those that are the most average looking.

Experiments using composite images based on hundreds of women's faces have demonstrated that when people are confronted with the image of Ms. Average Face World—regardless of the viewers' ethnic background—they uniformly agree that she is more beautiful than the individual faces that make up the composite. In short, as a species, we find the average face to be the most beautiful.

The face is the means by which we communicate. Of all the motor skills that infants must master in the first few years of life, none is as important as mimicking the facial gestures of people around them.

Reverse side of the coin

Diseases and injuries can create asymmetries and imbalances in the proportions of the face that can be fatal for social interaction.

Because the face is many times the calling card for a disease, people often intuitively shy away from disfigured people. Looking different on the outside, of course, doesn't mean that you are different on the inside. Nevertheless, there is no denying that a physical transformation of our face powerfully affects the way we view ourselves and the way others respond to us.

Although beauty is best defined by the kindness, compassion, intelligence, and warmth of an individual, it is also expressed as optimism and perseverance in the face of adversity.

For those who have suffered a mishap or a disease that leaves them looking different, reconstructive surgery and/or prosthetics based on osseointegrated implants can be decisive for living a good life outside the confines of the home. <

→ More to explore!
To view Dr. Helms' TEDxTalk from Stanford on the subject of "Reconsidering Beauty", please visit:
bit.ly/TED-helms

Nobel Biocare NEWS

Printed on non-chlorine bleached FSC-certified paper.

Read us online at:
nobelbiocare.com/news

Headquarters

Nobel Biocare Services AG
P.O. Box
8058 Zürich-Flughafen, Switzerland

Offices:
Balsberg, Balz-Zimmermann-Strasse 7
8302 Kloten, Switzerland
Phone +41 43 211 42 00
Fax +41 43 211 42 42

Web contact: www.nobelbiocare.com/contact

Europe and Russia

Austria
Nobel Biocare Austria
Phone: +43 1 892 89 90

Belgium
Nobel Biocare Belgium
Phone: +32 2 467 41 70

Denmark
Nobel Biocare Denmark
Phone: +45 39 40 48 46

Finland
Nobel Biocare Finland
Phone: +358 20 740 61 00

France
Nobel Biocare France
Phone: +33 1 49 20 00 30

Germany
Nobel Biocare Germany
Phone: +49 221 500 85 590

Hungary
Nobel Biocare Hungary
Phone: +36 1 279 33 79

Ireland
Nobel Biocare Ireland
Phone: toll free 1 800 677 306

Italy
Nobel Biocare Italy
Phone: +39 039 683 61
Cust. support: toll free 800 53 93 28

Lithuania
Nobel Biocare Lithuania
Phone: +370 5 268 3448

Netherlands
Nobel Biocare Netherlands
Phone: +31 30 635 4949

Norway
Nobel Biocare Norway
Phone: +47 64 95 75 55

Poland
Nobel Biocare Poland
Phone: +48 22 549 93 50
Cust. support: +48 22 549 93 52

Portugal
Nobel Biocare Portugal
Phone: +351 22 374 73 50
Cust. support: toll free 800 300 100

Russia
Nobel Biocare Russia
Phone: +7 495 974 77 55
Cust. support: toll free 8 800 250 77 55

Spain
Nobel Biocare Spain
Phone: +34 93 508 8800
Cust. support: toll free 900 850 008

Sweden
Nobel Biocare Sweden
Phone: +46 31 335 49 00
Cust. support: +46 31 335 49 10

Switzerland
Nobel Biocare Switzerland
Phone: +41 43 211 53 20

United Kingdom
Nobel Biocare UK
Phone: +44 208 756 3300

North America

Canada
Nobel Biocare Canada
Phone: +1 905 762 3500
Cust. support: +1 800 939 9394

USA
Nobel Biocare USA
Phone: +1 714 282 4800
Cust. support: +1 800 322 5001

Central/South America

Brazil
Nobel Biocare Brazil
Phone: +55 11 5102 7000
Cust. support: 0800 169 996

Chile
Dental Biocare Chile
Phone: +56 2 2706 5843

Colombia
Hospimedics S.A.
Phone: +57 1 620 9410
Cust. support: +57 1 620 9410

Mexico
Nobel Biocare Mexico
Phone: +52 55 524 974 60

Asia/Pacific

Australia
Nobel Biocare Australia
Phone: +61 2 8064 5100
Cust. support: toll free 1800 804 597

China
Nobel Biocare China
Phone: +86 21 5206 6655
Cust. support: +86 21 5206 0974

Hong Kong
Nobel Biocare Hong Kong
Phone: +852 2845 1266
Cust. support: +852 2823 8926

India
Nobel Biocare India
Phone: +91 22 6751 9999
Cust. support: toll free 1 800 22 9998

Japan
Nobel Biocare Japan
Phone: +81 3 6717 6191

New Zealand
Nobel Biocare New Zealand
Phone: +61 2 8064 5100
Cust. support: toll free 0800 441 657

Singapore
Nobel Biocare Singapore
Phone: +65 6737 7967
Cust. support: +65 6737 7967

Taiwan
Nobel Biocare Taiwan
Phone: +886 2 2793 9933

Africa

South Africa
Nobel Biocare South Africa
Phone: +27 11 802 0112

Europe and Middle East

Distributor Markets

Bahrain, Bulgaria, Croatia, Cyprus, Czech Republic, Greece, Iran, Iraq, Israel, Jordan, Kuwait, Lebanon, Malta, Oman, Romania, Saudi Arabia, Serbia, Slovakia, Slovenia, Turkey, United Arab Emirates and Qatar
Phone: +48 22 549 93 56
Cust. support: +48 22 549 93 55